

“Crestal Window Sinus Lift,” minimally invasive, predictable, and systematic approach to sinus grafting.

Samuel Lee, DDS*, Grace Kang-Lee, DDS†, Kwang-Bum Park, DDS, MS, PhD‡, Thomas Han, DDS, MS §

Abstract

Background: The placement of dental implants in posterior maxilla is often a challenge due to pneumatization of maxillary sinus. Dental surgeons have predictably overcome these obstacles by performing bone grafting procedures such as lateral window technique (modified Caldwell-Luc). But, morbidity has been a concern due to postoperative bruising, pain, and swelling. To reduce the morbidity, many internal (crestal) approaches to sinus grafting were introduced using osteotome, reamers, tapping drills, piezo, ISM, HSC, etc. But still, all these internal techniques for sinus grafting are difficult to predict their results because of lack of visibility when opening sinus floor and manipulating Schneiderian membrane.

Purpose: Presenting a new sinus grafting technique that is systematic and predictable. This system utilizes crestal approach to reduce morbidity. Unlike the other crestal approaches to sinus grafting, the uniqueness of this system is that it is not a blind technique and the result of membrane elevation is comparable to that of lateral approach.

Conclusion: The new systematic approach to internal sinus grafting is simple, predictable, without morbidity associated with lateral window technique.

KEY WORDS: Sinus, grafting, Lift, dental implants, lateral window, crestal window, internal sinus lift, crestal sinus lift, sinus elevation, osteotome, Schneiderian, sinus membrane, minimally invasive sinus surgery

Introduction

The treatment of posterior edentulism has been a challenge for dental physicians due to a poor bone quality and quantity (due to pneumatization of maxillary sinus). We have overcome these obstacles by bone condensing and bone grafting into a maxillary sinus under the Schneiderian membrane.¹⁻¹⁸ Bone grafting into sinus have produced predictable results enabling clinicians to place longer implants for more stable prosthesis with better and long term outcome.³ However, morbidity associated with the lateral window grafting procedure has been a concern.^{5, 6, 7, 15, 17, 18} Severe bruising, swelling, and pain are the common postoperative complications due to a flap elevation beyond the mucogingival junction.^{5, 6, 7, 15, 17, 18} The intraoperative complication that arises from the rupture of intraosseous branch of posterior superior artery (branch of maxillary artery) is panic-stricken¹⁵. Moreover, the technical nature of lateral window procedure is easily accompanied with the possibility of the Schneiderian membrane perforation while

opening an window and elevating a sinus membrane. Therefore, nowadays, many internal (crestal) approaches to sinus grafting have been introduced such as osteotome^{5, 6, 7}, reamers¹⁷, tapping drills¹⁸, piezo, ISM¹⁷, HSC¹⁵, etc. Nevertheless, all the internal techniques for sinus grafting to this date are unpredictable for average clinicians, because of the lack of visibility when opening the sinus floor and manipulating the Schneiderian membrane.

A standard diameter implant (4.0mm) has been a great solution for premolar areas, but it has some limitations in the molar area resulting a poor emergence profile²¹, fracture of implants²⁰, crestal bone strain¹⁹, and a narrow occlusal table. Minimum of 5mm to 8mm implants in diameter will overcome the poor bone quality by increasing the bone to implant contact surface area as well as making a superior emergence profile²¹. Such diameter of implants in molar area also decreases the fracture rate of implants, crestal bone stress, and allows fabrication of a natural size occlusal table²⁰.

Use of wide diameter implants, which is more appropriate for molar restorations as described above, has opened a new door to sinus grafting. Crestal window, instead of lateral window, is made with trephine bur to elevate a sinus membrane and graft bone into the sinus with a direct visualization (not a blind technique like previous crestal approach techniques published). The new innovation in sinus grafting described in this paper makes sinus grafting easy and predictable, without the cost of morbidity associated with the lateral window technique.

Description of the Innovation/Method

Flap Elevation

Incision design that is at least 2 mm more palatal than the implant position and a flap elevation that does not open beyond the mucogingival junction is recommended (figure 1). This type of incision design allows minimal pain, prevention of oral antral communication in case of perforation, unilateral retraction of flap, and an option of doing one or two stage implant placement without losing keratinized tissue.

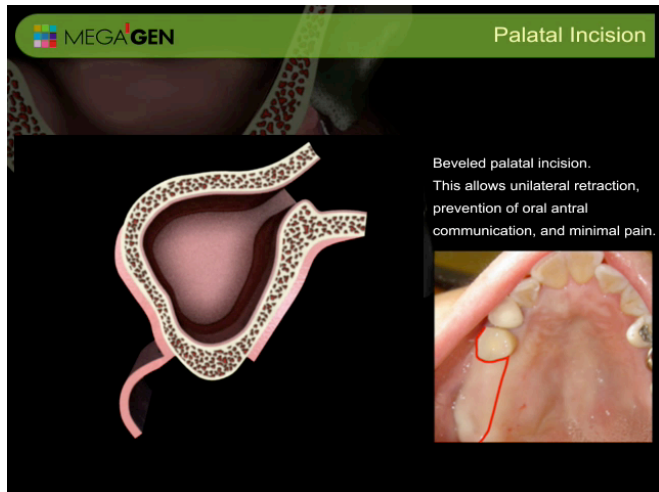


Figure 1. Palatal incision for minimal pain, prevention of oral antral communication in case of perforation, unilateral retraction of flap, and allows option of doing one or two stage implant placement without losing keratinized tissue.

Location of crestal window

Lowest point of sinus floor is located with an aid of panoramic radiograph (figure 2). It is more favorable if this position coincides with implant

position. For example, if implant placement on #2, 3, and 4 are anticipated and #3 site is the lowest sinus floor, #3 site is used to lift sinus membrane. The rationale behind this method is that the elevation is done from the bottom to up. That being the case, this approach is easier to elevate from the lowest point.

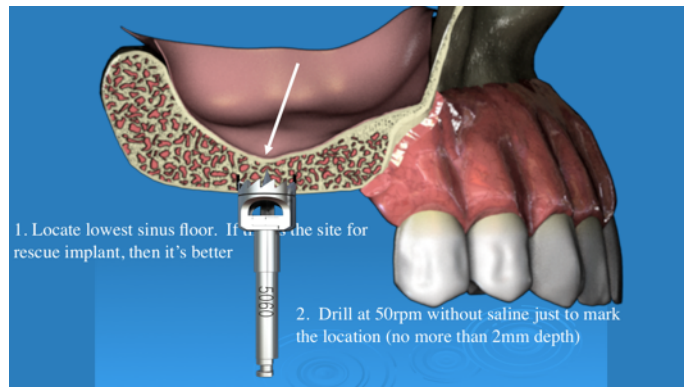


Figure 2. Internal sinus lift initiated from lowest location.

Crestal window with set of specially designed trephine burs[#]

Round windows is made on the crestal bone with a specially designed trephine bur which is 1 mm smaller in diameter than the final implant size. For example, if 6 mm implant is anticipated, 4.0 mm inner diameter and 5.0 mm outer diameter is used. Unlike the conventional trephine that uses 700-1000 rpm with an ample amount of irrigation, this technique utilizes a lower speed, 40-50 rpm without irrigation, for that reason it is called the “Waterless technique.¹⁸” Waterless technique has many advantages of not using saline irrigation. For instance, a patient is more comfortable during the waterless procedure, a surgeon is able to collect more autogenous bone, and this technique is more friendly to vital structures such as sinus membrane, lingual plate, buccal wall, arteries, and nerves. Moreover, this technique enables implant position and angulation more precise because it is performed at a lower speed¹⁸.

Trephining at a precise location can be challenging due to a drifting nature of the trephine bur. In order to minimize heating of bone and to maximize visualization and precision of trephine bur, a newly designed “pointed trephine[#]” is used at the speed of

50 rpm without irrigation (figure 3). The pointed trephine is used to mark the location for the crestal window, and only drills into the cortical bone of the crest (figure 4).

The second step of this system utilizes the trephine that has adjustable stopper#. One millimeter short of the sinus floor from the crestal ridge is estimated with an aid of radiograph, and the “stopper trephine” is used to set that length inside the trephine. For example, if 6 mm of bone height is anticipated, then the stopper is set at 5 mm within the trephine. Using 50 rpm speed, the “stopper trephine” is used to take the bone core out (figure 5). If the sinus floor is weak and relatively flat, the sinus floor will fracture off and expose the Schneiderian membrane (figure 6). However, if the sinus floor is dense or in an incline plane, it will leave about 1 mm of cortical bone (floor of sinus).

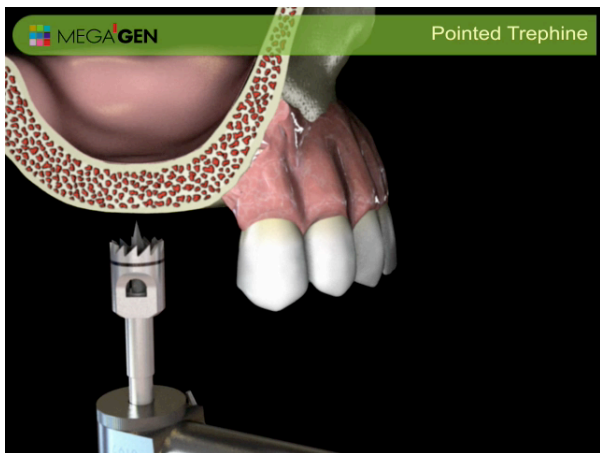


Figure 3. Pointed trephine to mark precise location of crestal window position.

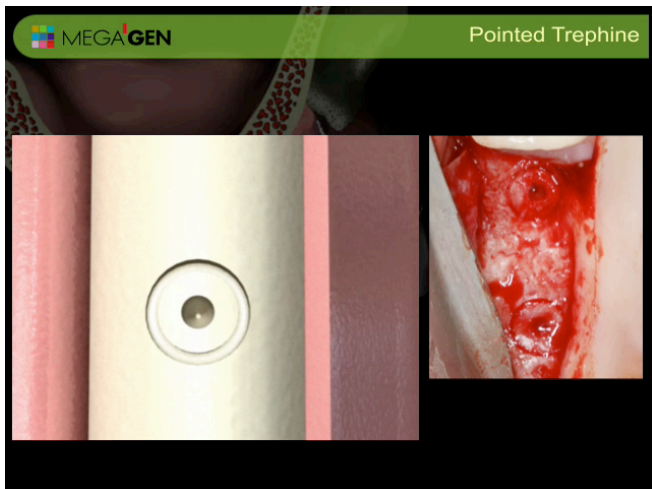


Figure 4. After use of pointed trephine. Pointe trephine is used

to mark the position of implant not penetrating more than 2 mm.

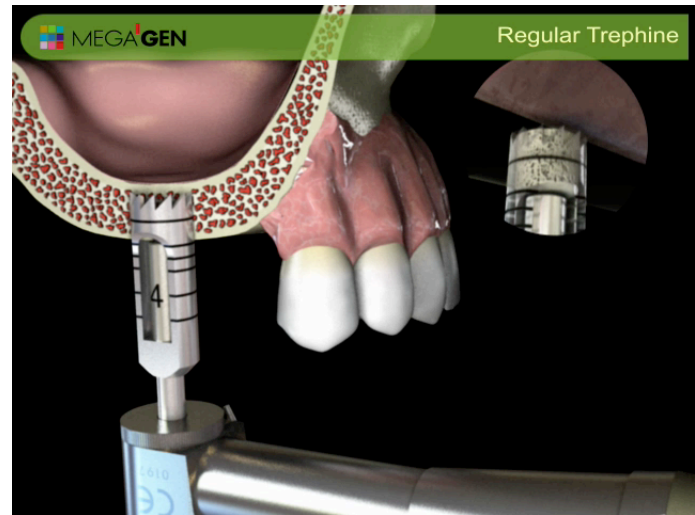


Figure 5. Stopper trephine used at 50 rpm 1 mm short of sinus floor.

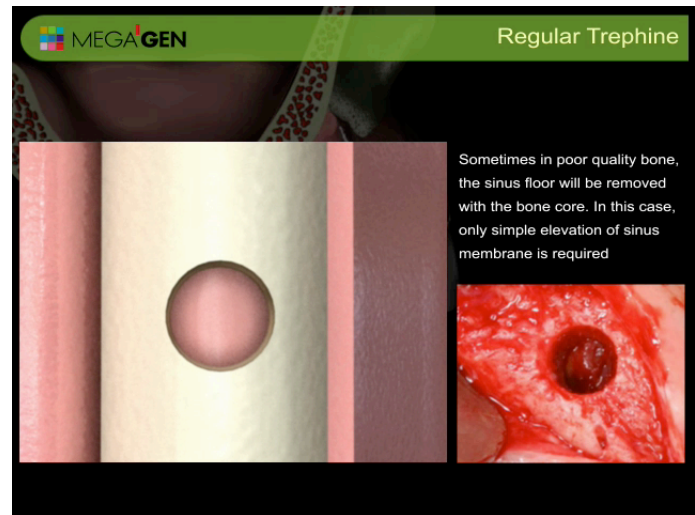


Figure 6. Flat sinus floor will be taken out with trephine bur leaving just sinus membrane most of time.

If cortical bone is still intact after the use of the trephine bur, then the “sinus diamond bur#” is used to open the sinus floor without perforating the sinus membrane (figure 7 and 8). This is done very predictably because of the formula below:

$$\text{Pressure} = \text{Force} / \text{Area}$$

The force is minimized by utilizing the stopper at the shoulder of the diamond bur. The diamond surface will grind out bone rather than cutting it. These fine bone particles will act as a buffer between the sinus membrane and the diamond bur creating a larger

surface contact, which in turn reduces the pressure on the membrane. In addition, a large diameter diamond bur is used, rather than a small one to increase the surface area, which in fact, also decreases the pressure on the Scheiderian membrane. This concept is similar to the “nail bed” (figure 7), that does not puncture magician’s skin.

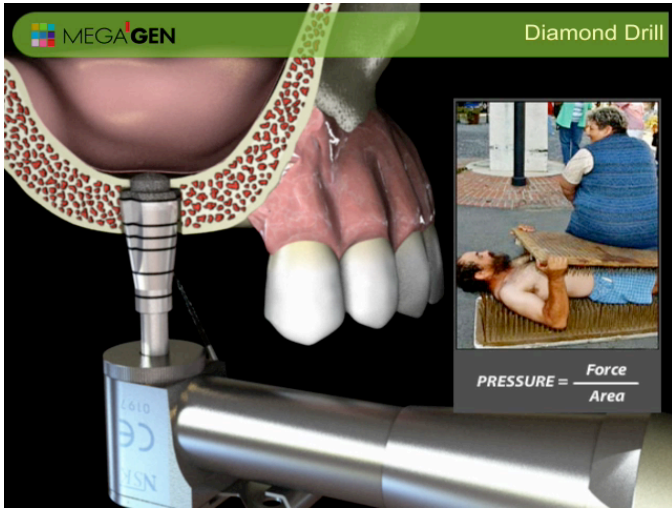

figure 7. diamond bur that minimizes pressure on sinus membrane by putting minimal force and maximizing contact surface.

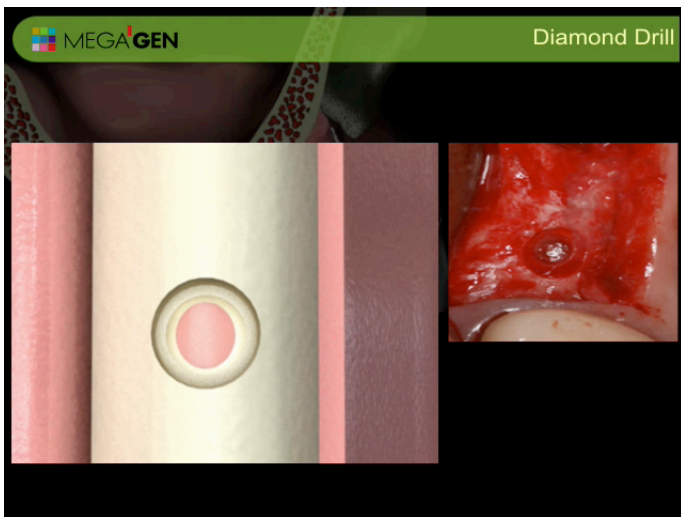


Figure 8. After the use of the “sinus diamond bur.” the membrane is still intact.

Next, the mushroom elevator[#] is used as a probe to feel the sinus floor to detect any membrane exposure. Sinus floor is never flat, therefore it is common to find an initial sinus opening not on the center of osteotomy, rather on the corner of

osteotomy depending on the incline plane of the sinus floor. Once a slight drop into the sinus membrane is felt, the elevation of the membrane is initiated with the “mushroom sinus elevator” (figure 9), and it is also used to break away the remaining ledges of the bone that interfere with the sinus membrane elevation (figure 10). Subsequently, the “Cobra sinus elevator[#]” is used to further elevate the sinus membrane, and to scrape the sinus floor to promote bleeding in the sinus cavity (figure 11 and 12).

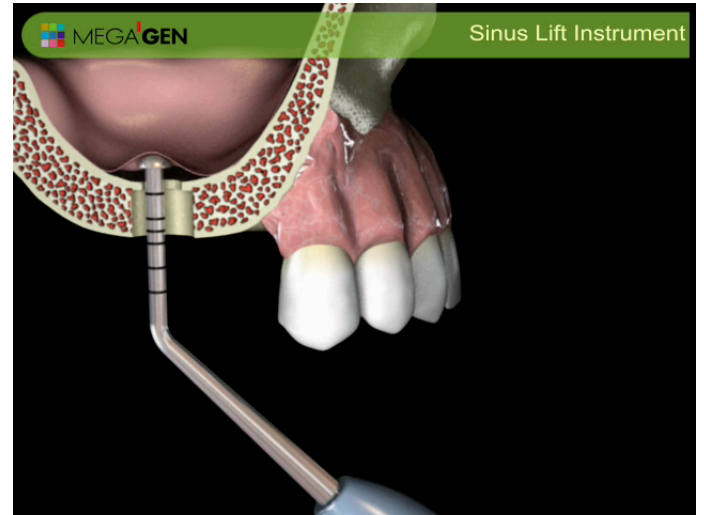


Figure 9. Mushroom elevator to initial sinus membrane elevation.

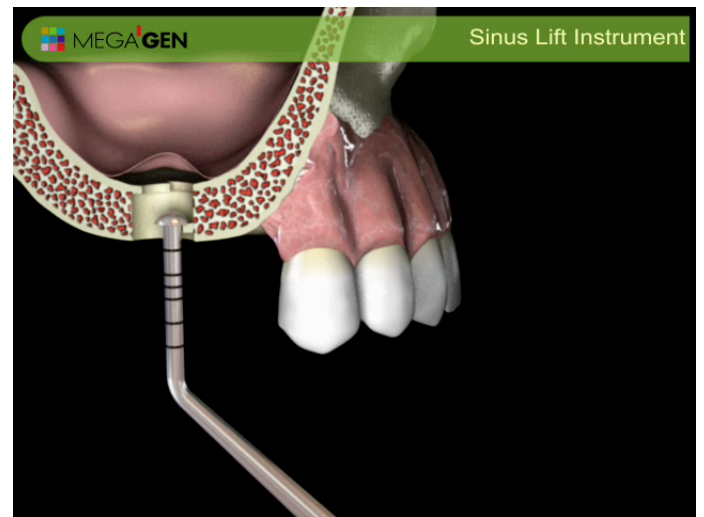


Figure 10. Mushroom elevator to break away ledge of bone that interferes with sinus elevation.

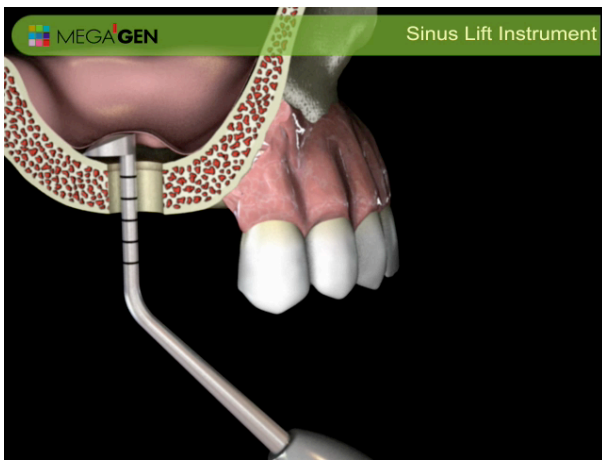


Figure 11. Cobra elevator to further elevate sinus floor distally and medially. Also used to scrape sinus floor to promote bleeding.

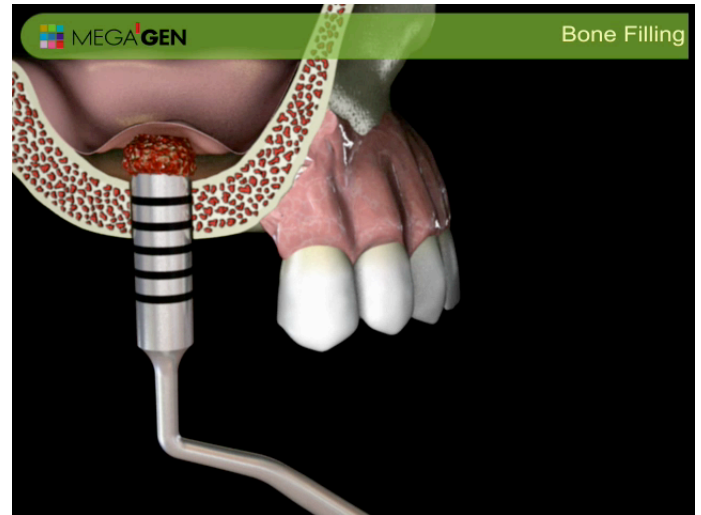


Figure 12. vertical condensation of autogenous bone (graft collected from the trephine) only to just above residual bone height.

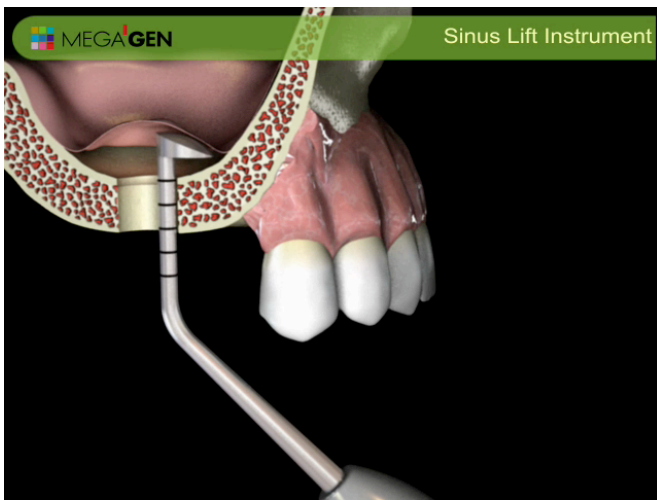


Figure 11. Cobra elevator to further elevate sinus floor mesially and laterally. Also used to scrape sinus floor to promote bleeding.

Bone Condensing

The lateral condensation (figure 13) of bone is more critical than the vertical condensation (figure 12) to decrease the pressure on the sinus membrane. This method facilitates a healing time by increasing the blood supply from the lateral and medial walls, thus this leads to a better prognosis and long term success. By the way, the cross sectional slide from the CT scan is crucial to verify the elevation of lateral and medial walls rather than a dome shape graft as seen in the most internal techniques (figure 28, 30, 35).

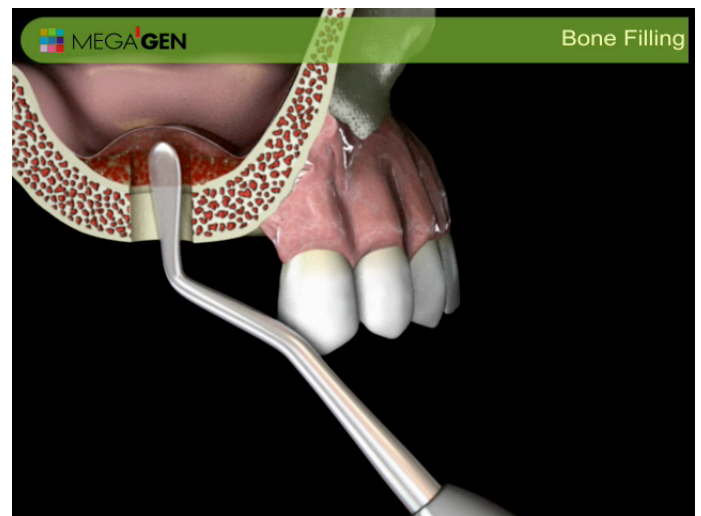

Figure 13. Lateral condensation of bone graft to increase blood supply by graft entering lateral and medial wall, instead of making dome shape grafting as seen on other internal sinus grafting procedures.

Insertion of implant

Skipping the last drill in the sequence of implant drills is recommended to achieve a better bone compaction and improve the initial stabilization of implant (figure 14). If an implant is loose, a larger healing cap is recommended to prevent implant dropping into sinus cavity, especially if the residual bone height is short.

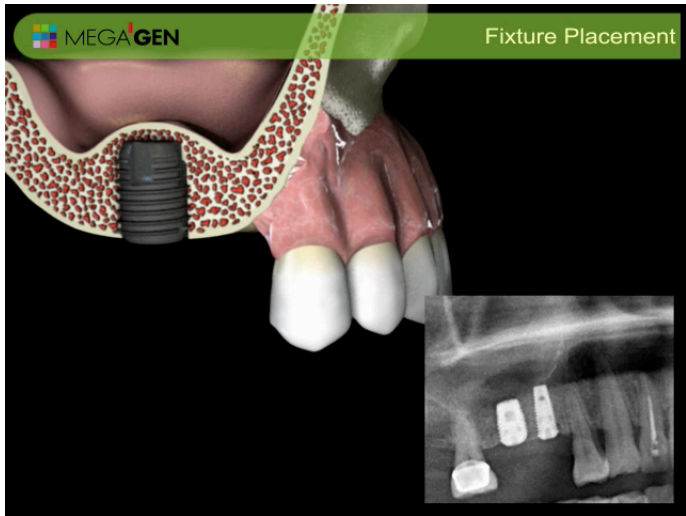


Figure 14. slow insertion of implant. Under prepping osteotomy is crucial to achieve good initial stabilization. Then adjacent implants can be inserted after sufficient sinus grafting.

Case report 1

This is a 29 years old female asian patient who had an extraction of #14 three months prior to implant surgery and #15 edentulism for 5 years. She is a non smoker and a healthy individual. A preoperative radiograph shows 4-6 mm of a residual bone height. Ostium is wide open and there were no signs of sinusitis.

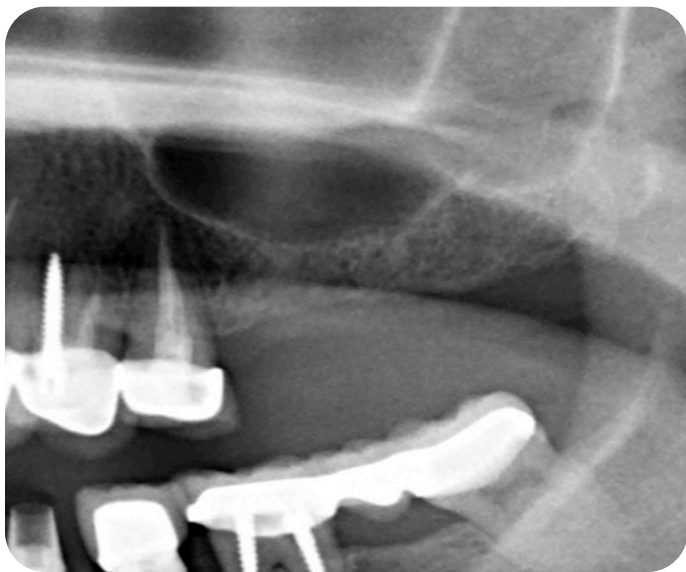


Figure 15. preoperative radiograph showing only 4-6 mm of residual bone height.

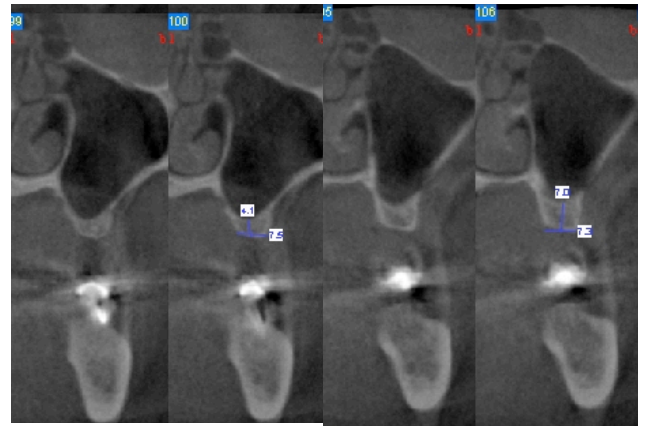

Figure 16. Cross section of sinus shows thin sinus membrane, no signs of sinus disease and patency of ostium. Sinus floor is relatively flat.

The cross section of CT shows healthy sinus, but her sinus membrane is thin and gingival bio type is a thin type as well. There is no known study correlating between the gingival biotype and the thickness of a sinus membrane, but through the author's clinical experience it is observed that a thin gingival biotype tends to have a thinner sinus membrane unless he/she is a smoker.

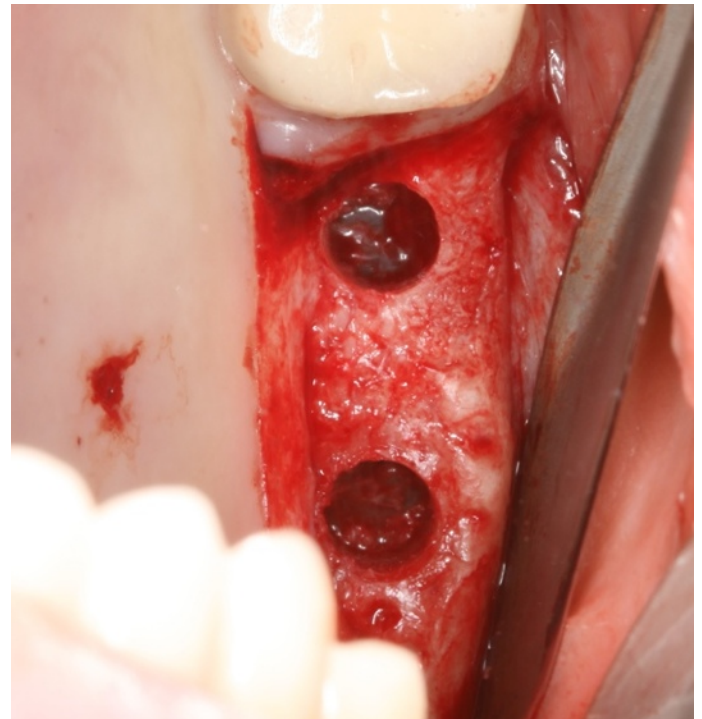


figure 17. after bone core is removed sinus floor came out with it. Thin sinus membrane is observed with some bone ledge still intact (which can be removed with mushroom elevator).

The patient's sinus floor is relatively flat, thus it was expected that the sinus floor can be removed with the bone core after the use of trephine with the stopper (figure 17). Trephine at the low speed, 50 rpm ("Waterless technique") is used to take out the bone core. The rotation of the bone core within the trephine bur is a clinical indication that the sinus floor is broken and no further apical pressure of trephine is recommended to avoid cutting the sinus membrane.

Autogenous bone collected from the trephine is made into a particulate graft and condensed into the maxillary sinus. After the elevation of sinus membrane, slow bone compaction is introduced by inserting a condenser no more than the initial height of the residual bone (figure 18). Then, the lateral condensation is achieved by the use of "sinus spreader" (figure 19)

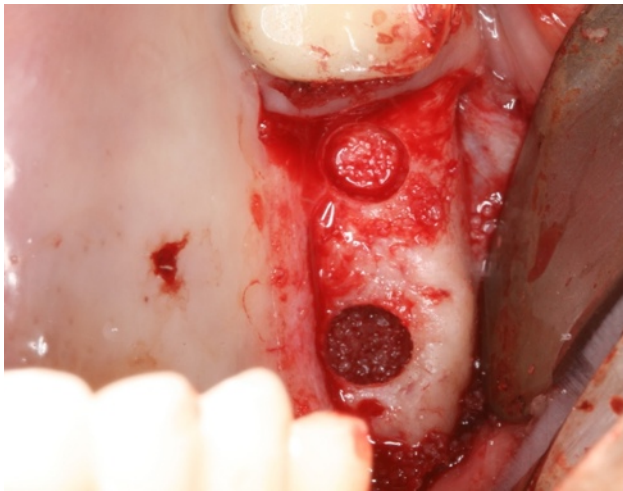


Figure 18. vertical condensation into sinus no more than initial height of sinus floor.

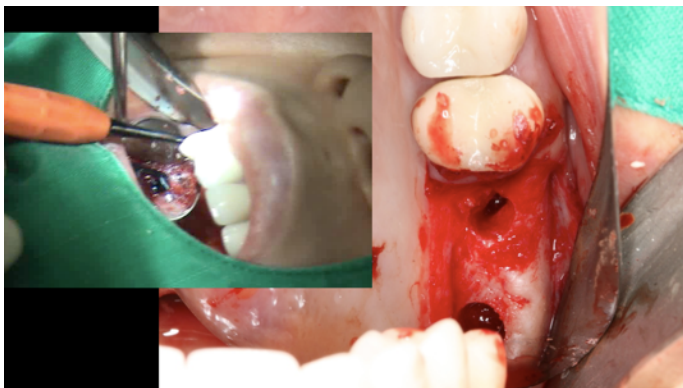


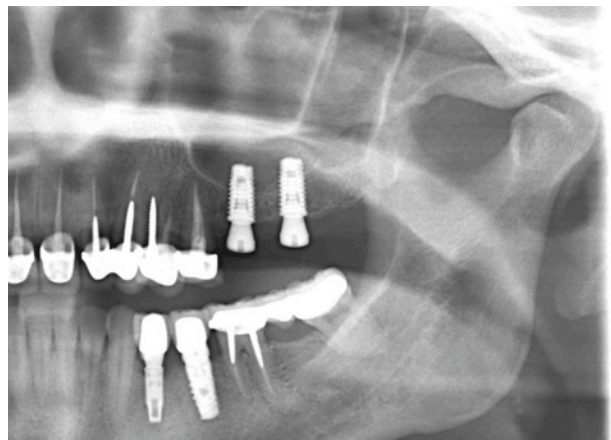
Figure 19. after lateral condensation with "spreader."

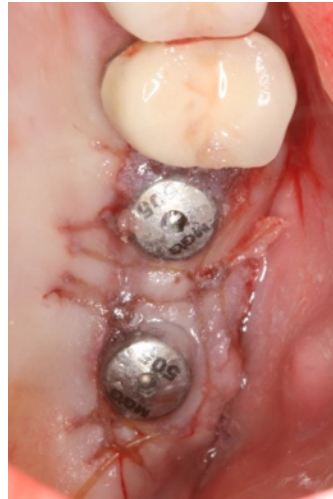

Figure 20. after suture. Notice that by doing palatal incision we have preserved attached gingiva on buccal side.

Implant osteotomy is under-drilled in diameter, so a good initial stability is achieved by allowing one stage implant surgery as well as condensing a poor quality bone. Initially, we started the surgery with the palatal incision, so we have an option of doing two stage surgery with the incision line away from the implant site as well as one stage with the preservation of keratinized tissue (figure 20).

Panoramic and CT scan should be taken after the surgery to verify proper grafting of maxillary sinus without perforation. It is more important to note the horizontal compaction of the bone graft touching the medial and lateral walls, which maximize the blood supply to the graft and determines the longevity of the graft after loading.



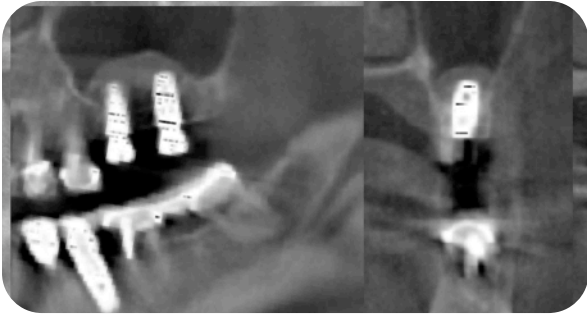


Figure 21. Postoperative radiograph. Note excellent lateral condensation of graft reaching medial and lateral wall of sinus.

Case 2

This is a 53 years old male asian patient who is healthy and a non-smoker. Ostium is patent and no sign of sinus disease is detected. The lowest point on the sinus floor was located on #3 area with the residual bone height of 6.5mm. In this case, due to a high bone density of the sinus floor, the trephine core came out without the sinus floor. “Sinus diamond bur” was used to expose the Schneiderian membrane safely (figure 22). Then, elevation of membrane and bone grafting was achieved using DFDBA** mixed with autogenous bone graft (figure 22). Overgrafting was planned due to a high shrinkage rate of DFDBA** (figure 23).

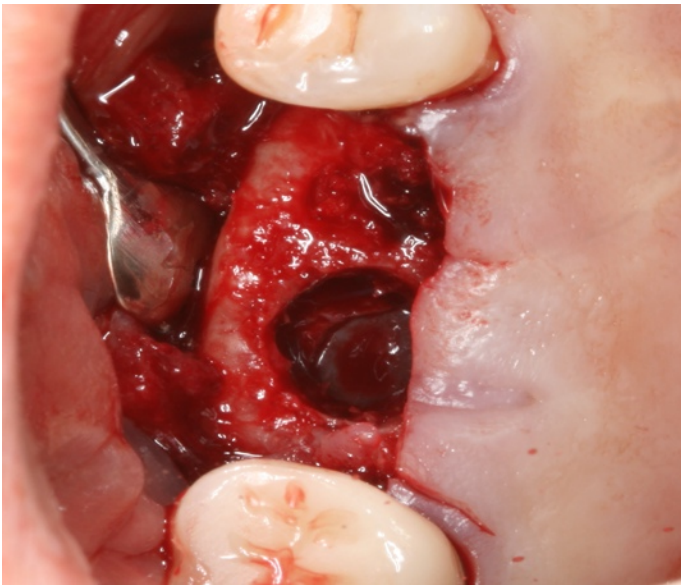

figure 22. after 5 mm trephine, sinus floor was still intact. Therefore, “Sinus diamond bur” used to grind out the floor. Visualization of sinus membrane is clearly seen.

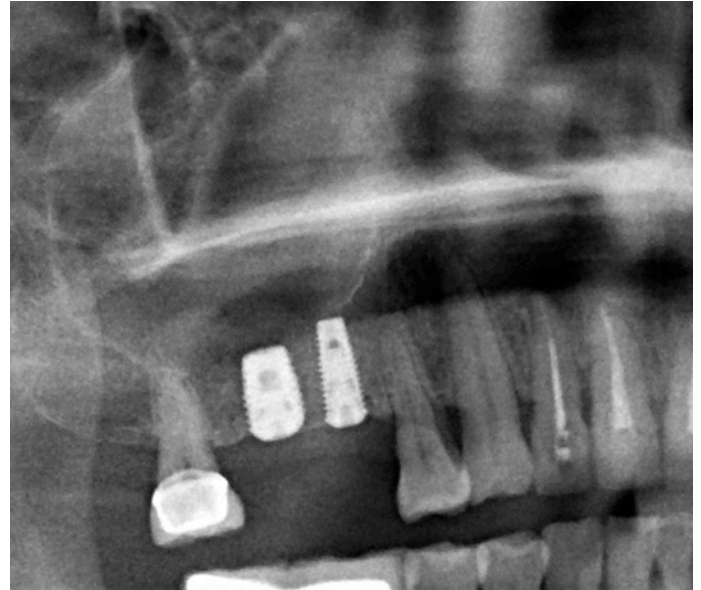


Figure 23. 6X8.5mm and 4X10mm implant placed after grafting with DFDB and autogenous bone graft internally into maxillary sinus. To anticipate shrinkage, over grafting has been achieved.

Case 3

This is a 60 years old asian patient who is a smoker, otherwise healthy individual. The residual bone height is only about 1.5mm on #14 site. #14 site was used to lift the sinus (because it is the lowest point), then #13 implant was placed after grafting. Sinus diamond bur is used to penetrate into the bone directly instead of using the trephine bur because the residual bone height is only 1.5 mm.

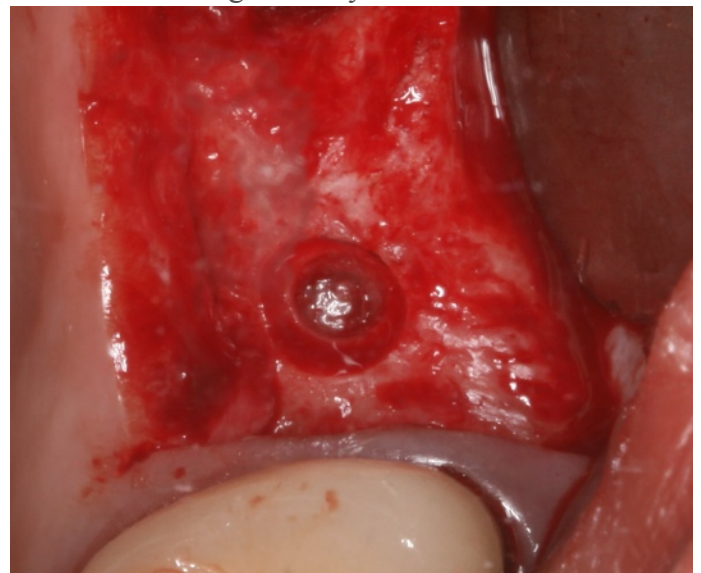


figure 24. after use of sinus diamond bur. Note sinus membrane on the center of the ring.

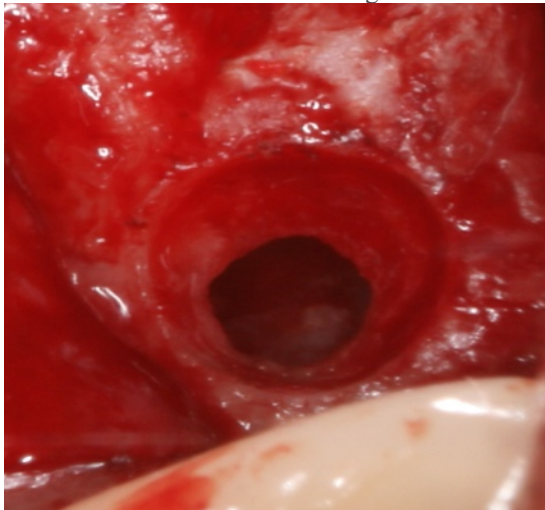


figure 25. after elevation of membrane with mushroom elevator.

After a visual confirmation of the sinus membrane exposure, the membrane elevation was done with the “mushroom elevator.” Then, the ledge of bone was removed with osteotomy drill at low speed using the “waterless technique” (figure 26). After removal of the ledge of bone, introduction of “cobra elevator” was possible to further elevate the sinus membrane in all directions. Bone condensed into the sinus, then implant was inserted with skipping the last drill sequence (4.3 mm diameter drill instead of 4.6 mm drill for 5.1 mm implant). A good primary stabilization was achieved (figure 27).

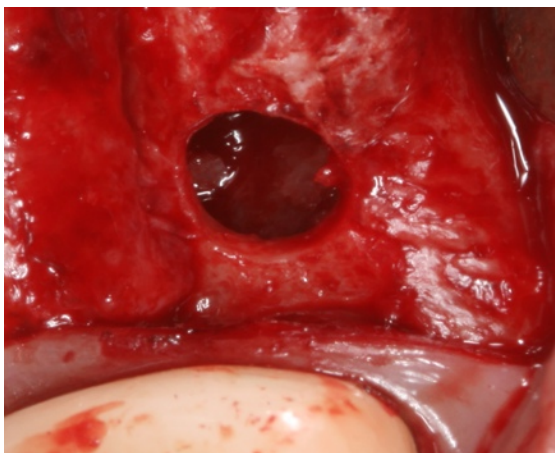


figure 26. ledge of bone removed with 4.3 mm implant osteotomy drill at low speed (Waterless technique¹⁸).

As seen on the figure 26, the crestal window technique is easier if a residual bone height is thin.

Moreover, thinner residual bone height permits a better access and visualization. The elevation of membrane with the cobra elevator is easier if there is less residual bone height, because there are less interference of bone on the instrument while elevating the membrane. Movement of the Schneiderian membrane is observed as a patient is breathing. This serves as a confirmation that the sinus membrane is intact after elevation. Then, as a final step prior to bone grafting, the cobra elevator is used to make bleeding surface inside the sinus by scraping the floor.

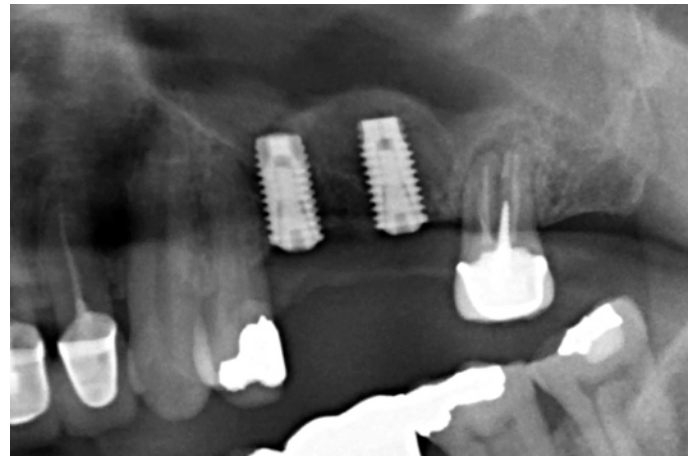


figure 27. Postoperative radiograph showing 12 mm of elevation from #14 site. Only 1-2 mm residual bone height.

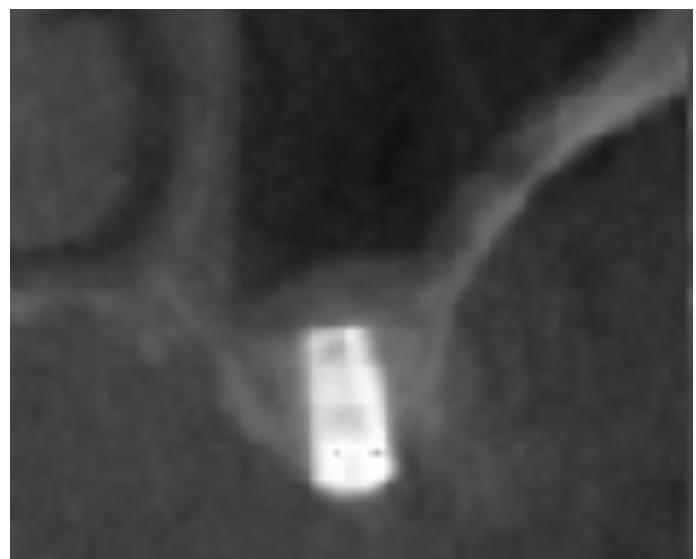


figure 28. Postoperative radiograph showing good lateral condensation. Note relatively thick sinus membrane due to smoking.

A cross section from the CT scan shows that the medial and lateral walls are fully elevated to maximize the blood supply to the graft (figure 28). Note the thickness of the Scheneiderian membrane on the unelevated lateral and medial wall, which is usually thickened due to smoking.

Case 4

This is a 53 years old patient who is healthy, but a heavy smoker. The Scheneiderian membrane is often thickened in smokers as discussed in case 3, which makes surgical elevation of membrane much more predictable. This author feels comfortable doing a sinus lift procedure if the thickness of the Scheneiderian membrane is less than 3mm, no clinical sign of sinusitis, and a patent ostium.

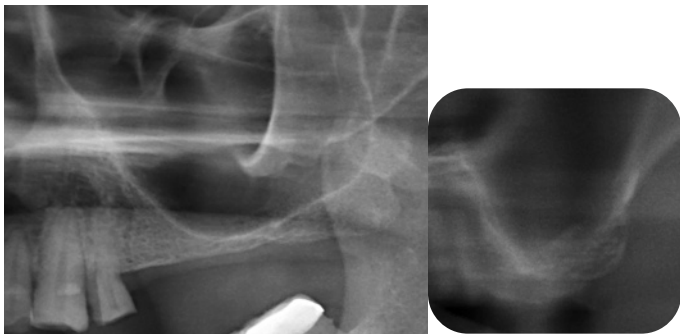


figure 29. Preoperative radiograph showing lowest sinus floor around #15 with 2 mm of residual bone height. #15 site was used to elevate sinus membrane using crestal approach.

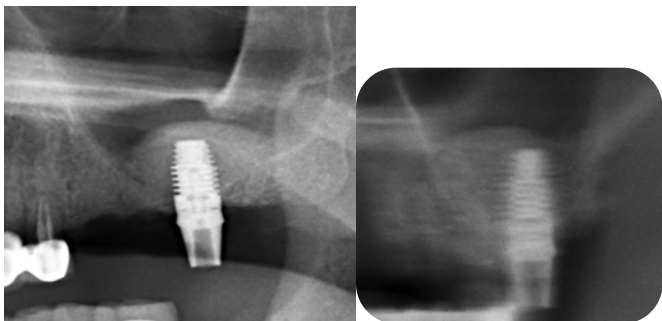


figure 30. After proper sinus grafting and insertion of 6X10 mm implant. Note the graft touching medial and lateral wall of sinus wall on the cross sectional view.

A preoperative radiograph shows only 2mm of bone height on #15 area (figure 29). The lowest point (#15) is used to elevate the sinus membrane and insert bone graft material. DFDB (1.5cc) was used mostly with the lateral condensation rather than the

vertical condensation (figure 30). Then, two more implants have been placed mesially on #13 and #14 area (figure 31). DFDB tends to resorb faster and cause more shrinkage than other bone graft materials; therefore, overgrafting of the material is indicated. However, advantage is that it is not too radiopaque. Therefore, when it gets replaced by a true bone, the clinician can have a visual confirmation by observing radiopacity from the newly formed bone as well and the new cortical bone formation on the new sinus floor (figure 32).

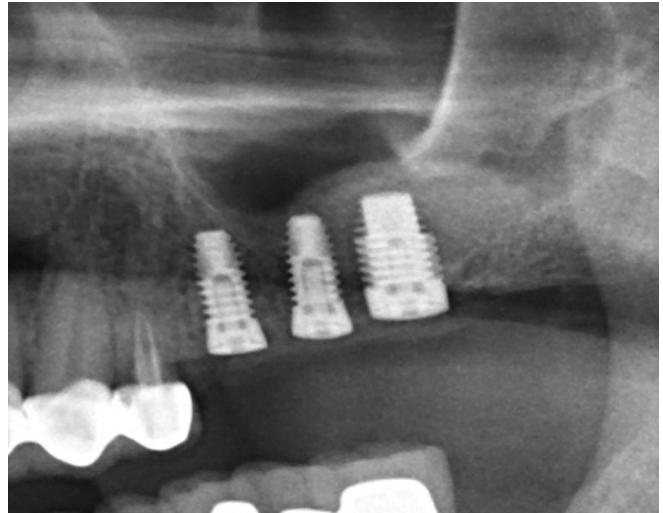


figure 31. Insertion of 4X10 mm implant into #13 and #14 site after bone grafting from #15 site.

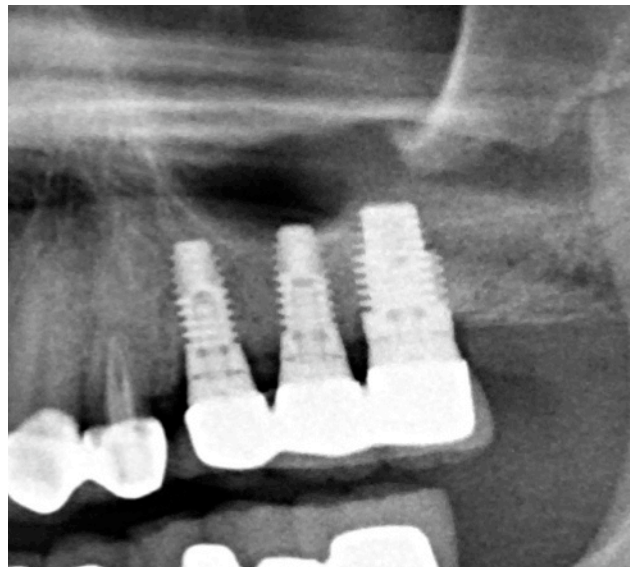

figure 32. Two year post operative showing new cortical bone formed on sinus floor confirming natural morphology of true bone

bone. Note shrinkage of bone graft due to faster resorbing nature of DFDB.

Case 6

The is a 39 years old asian patient who does not have a history of sinusitis and is not a smoker. Ostium patency is observed on the CT scan, and there is no clinical sign of sinus disease was detected prior to surgery. However, the residual bone height is only about 2 mm around #14 and #15 area (figure 33). Under prepping of osteotomy is crucial in this case to achieve a successful initial stabilization. As discussed above, the crestal window approach is easier if the residual bone height is thin like in this case. To avoid a bone shrinkage as observed in case 5, the author used a long lasting membrane (Lambone**) under the Scheneiderian membrane.

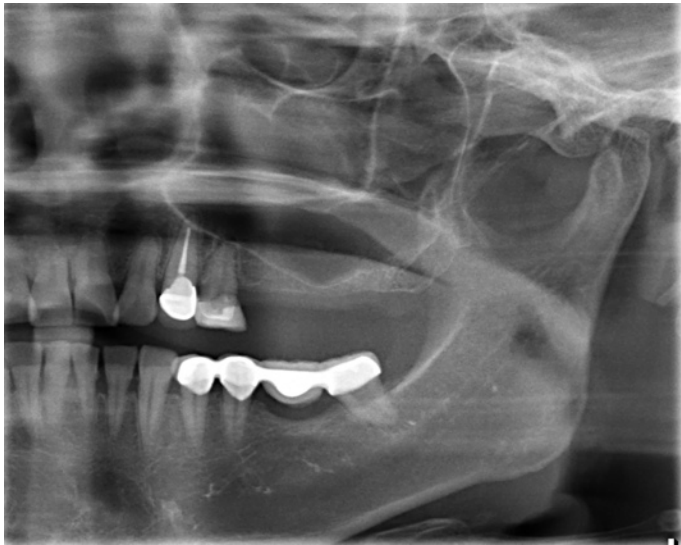

figure 33. Preoperative panoramic radiograph showing clear sinus cavity, but severe pneumatization leaving only 1-2 mm bone height at lowest point.

The crestal window in this case is only 4 mm in diameter. Therefore, insertion of the resorbable membrane is achieved by rolling the membrane (“Kim Bap Technique”) after soaking in saline with tetracycline¹⁹(figure 34). Lambone is tough and has an excellent plasticity, so once it is inserted into the sinus cavity via the crestal window, it will open up (go back to original shape) (figure 35).

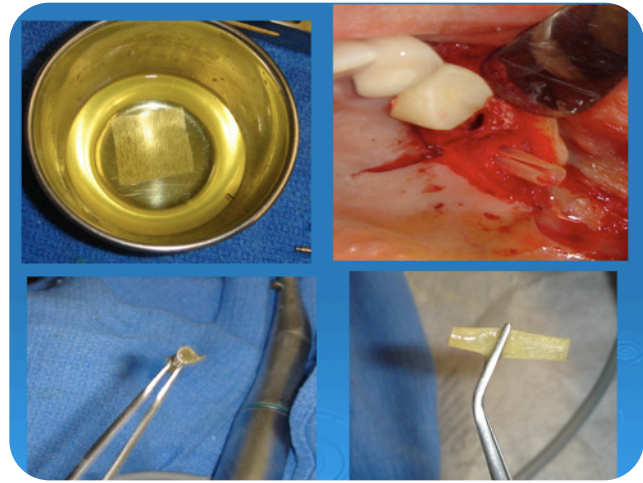


figure 34. after soaking resorbable membrane, Lambone, in tetracycline for 10 min, roll it up like Korean rice roll (“Kim Bap technique”) and insert into sinus cavity.

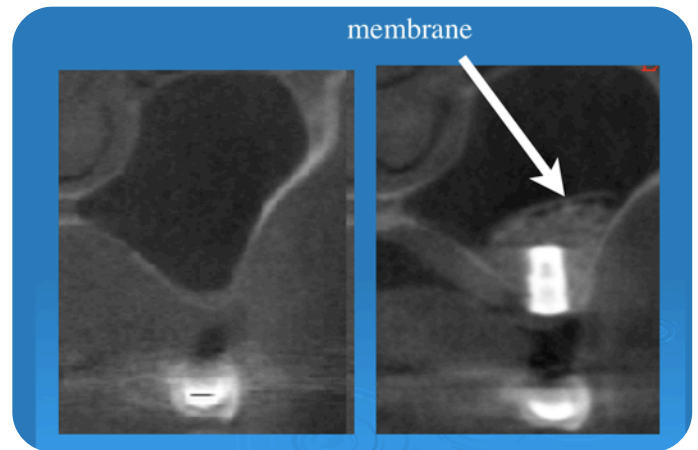


figure 35. Preoperative cross section on the left and postoperative cross section on the right. Note good lateral compaction of bone against sinus wall and membrane on top of graft to protect it from shrinkage.

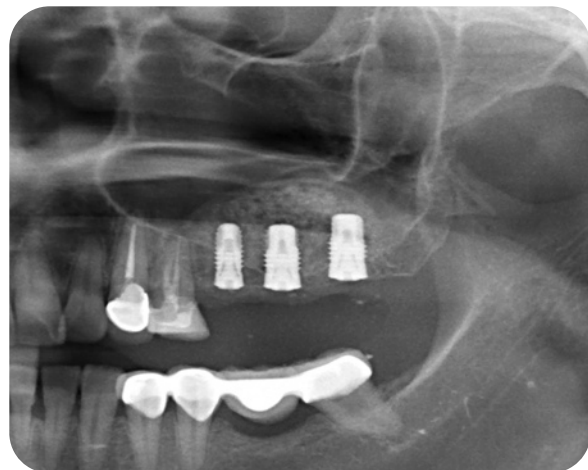

figure 36. Postoperative radiograph after internal sinus grafting and insertion of 4X10 mm on #13, 5X10 mm on #14, and 5X10mm on #15.

Discussion

As shown on many clinical cases above, the new “Crestal Window Technique” allows elevation of the Schneiderian membrane predictably without the morbidity associated with the lateral window technique, because the flap elevation does not extend beyond the mucogingival junction. With proper instruments (mushroom, cobra, bone carrier, vertical condenser, and lateral condenser) and tools (pointed trephine, trephine with stopper, and sinus diamond bur), the crestal window approach is predictable and results in similar outcome as the lateral window technique in terms of membrane elevation and bone condensing. However, as perforations do occur in the lateral window technique, perforations also can occur in the crestal window technique (mostly during membrane manipulation rather than during opening the crestal window).

Perforation of sinus membrane

In case of perforation, a primary closure is achieved since palatal incision was made. This prevents the possibility of oral antral communication especially in a case where the residual bone height is very thin. Non-resorbable membrane is recommended to be placed over the crestal window to prevent the soft tissue ingrowth. After 2-3 months after healing, a reattempt of the crestal window is most likely to be successful because a repaired sinus membrane (previously torn) is tougher in nature. Because of the low post operative discomfort associated with the procedure, patients accept the second attempt without much objection.

Time to load implant

The best indicator that the graft turned into a true bone without doing biopsy is an observation of new cortical bone formation on the newly formed sinus floor (figure 32). Typically it takes 3 + 1 month for every 1 mm of bone grafting. For example, if 5 mm of bone graft elevation was done, the new cortical bone will be formed around 8 months later (3 + 5 = 8

months). But, this formula slightly varies depending on the buccal lingual dimension of the sinus cavity.

Conclusion

The new innovative “Crestal Window” technique is a good alternative to the conventional lateral window technique. This technique results in a similar outcome as the lateral window technique without the morbidity associated with the procedure. Unlike other crestal approach to sinus lift, it is unique in that it is not a blind technique, and it does not result in a dome shape grafting (because the membrane is fully elevated palatally and laterally before the introduction of bone graft). The only disadvantage is that it requires use of 4.5 mm or larger implant placement. However, as discussed earlier, 5.0 mm diameter or larger should be used for the molar site anyway for a better emergence profile, less risk of implant fracture, and less crestal bone stress by minimizing the bending moment force.²⁰

* Dr. Samuel Lee is in private practice, First Choice Dental Group, Buena Park, CA, USA. He is the inventor of the tools described in this article.

† Dr. Grace Kang-Lee is in private practice, First Choice Dental Group, Buena Park, CA, USA.

‡ Dr. Kwang-bum Park is in private practice, Mir Dental Hospital, Dae Gu, Korea

§ Dr. Thomas Han, is in private practice, WPD, Los Angeles, CA, and also is clinical professor at Periodontal Department at UCLA.

All instruments mentioned above relating to “Crestal Window Sinus Grafting” is manufactured by Megagen Implant, Inc.

** DFDB is purchased from Pacific Coast Tissue Bank, Los Angeles, CA.

†† Lambone is purchased from Pacific Coast Tissue Bank, Los Angeles, CA.

Disclosure

The author of this article is the inventor of this “Crestal Window Sinus System,” and has financial interest with the product.

References

1. Tatum H Jr. Maxillary and sinus implant reconstruction. *Dent Clin North Am* 1986; 30:207-229.

2. Boyne PJ, James RA. Grafting of the maxillary sinus floor with autogenous marrow and bone. *J Oral Surg* 1980; 38:613-616.
3. Misch CE. Maxillary sinus augmentation for endosteal implants: organized alternative treatment plans. *Int J Oral Implant* 1987; 4:49-58.
4. Garg JN, Quinones CR Augmentation of the maxillary sinus. A surgical technique. *Pract Periodontics Aesthet Dent* 1997; 9:211-219.
5. Summers RB. The osteotome technique: part 3 – less invasive methods of the elevating the sinus floors. *Compendium* 1994; 15:698-704.
6. Summers RB. The osteotome technique: part 2 – the ridge expansion osteotomy (REO) procedure. *Compendium* 1994;15:422-426.
7. Summers RB. A new concept in maxillary implant surgery: The osteotome technique. *Compendium* 1994; 15:152-158.
8. Bori JE. A new sinus lift procedure: Sa-4/"O". *Dent Implantology Update* 1991; 2:33-37.
9. Smiler DG. The sinus lift graft: basic technique and variations. *Pract Periodontics Aesthet Dent* 1997; 9:885-893.
10. Bruschi GB, Scipioni A, Calesini G, Bruschi E. Localize Management of the sinus floor with simultaneous implant Placement: a clinical report. *Int J Oral Maxillofac Implants* 1998;13:219-226.
11. Toffler M. Site development in the posterior maxilla using Osteocompression and apical alveolar displacement. *Compend Contin Educ Dent* 2001;22:775-784.
12. Fugazzotto PA, De PS. Sinus floor augmentation at the time of maxillary molar extraction: success and failure rates of 137 implants in function for up to 3 years. *J Periodontol* 2002; 73:39-44.
13. Winter AA, Pollack AS, Odrich RB. Placement of implants in the severely atrophic posterior maxilla using localized management of the sinus floor: a preliminary study. *Int J Oral Maxillofac Implants* 2002; 17:687-695.
14. Soltan M, Smiler DG. Antral membrane balloon elevation. *J Oral Implantol* 2005; 31:85-90.
15. Chen L, Cha J. An 8-year retrospective study: 1,100 patients receiving 1,557 implants using the minimally invasive hydraulic sinus condensing technique. *J Periodontol* 2005; 76:482-491.
16. Wallace SS, Froum SJ. Effect of maxillary sinus augmentation on the survival of endosseous dental implants. A systematic review. *Ann Periodontol* 2003; 8:328-343.
17. Yamada J, Park H. Internal Sinus Manipulation (ISM) procedure: a Technical Report. *Clinical Implant Dentistry and Related Research*, volume 9, Number 3, 2007.
18. Lee S, Lee G. Minimally invasive sinus grafting with autogenous bone, *Implant Tribune*, Feb 2008. Vol 3 Issue 2.
19. Petrie C et al. Increasing implant diameter resulted in 3.5-fold reduction in crestal strain. *Clin Oral Impl Res.* 16 2005; 486-494
20. Davarpanah M. et al , Wide diameter implants: New concepts. *Int J Periodontics Restorative Dent* 2001;21;149-159
21. Degidi M, Piatelli A, Iezzi G, Carinci F. Wide-Diameter Implant: Analysis of Clinical Outcome of 304 Fixtures. *J Periodontol* 2007;78:52-58